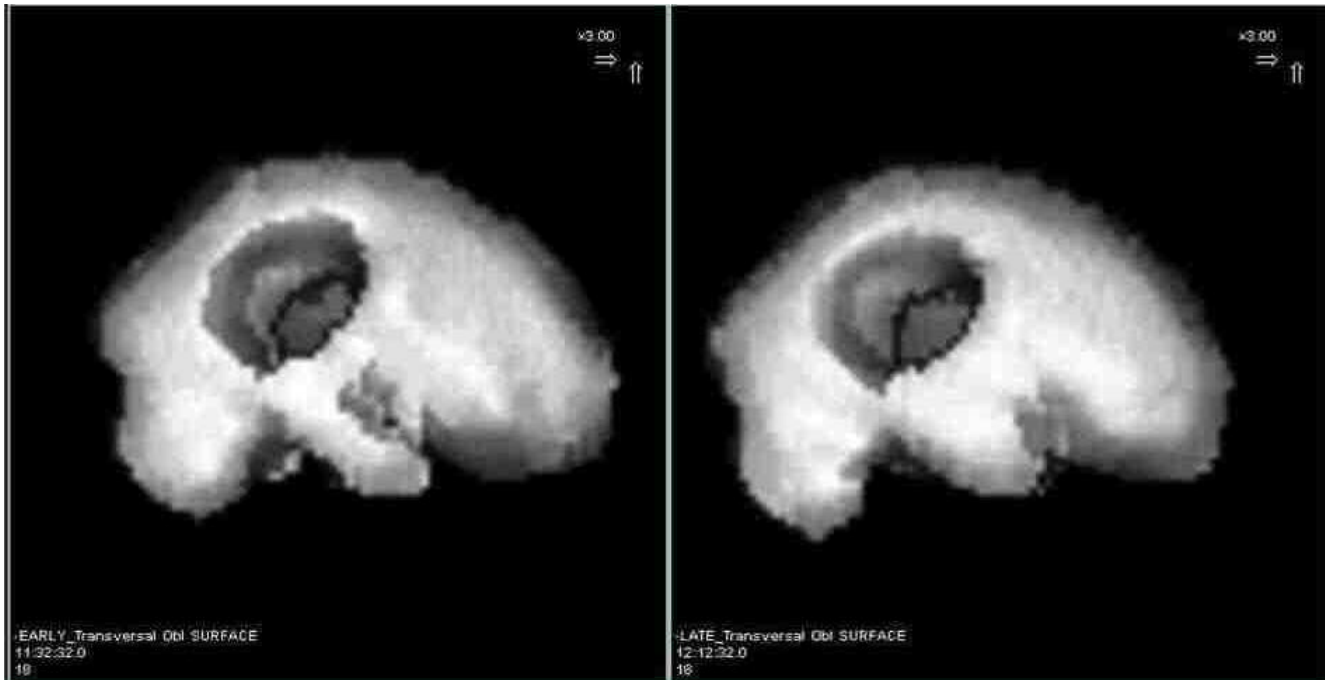
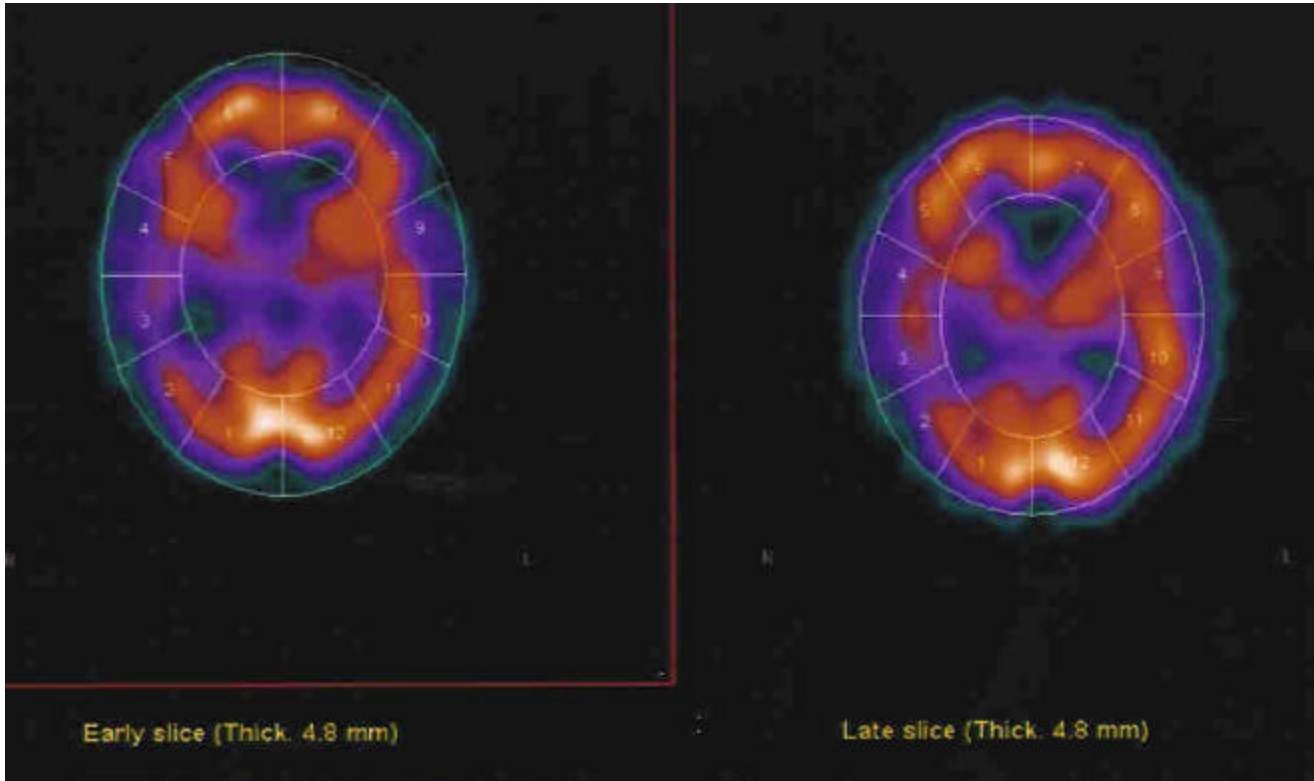


## Cerebral Vascular Accident — Right Side



### Cerebral Vascular Accident — Right Side

**A 74 year old male suffered a right hemisphere stroke on February 10, 2003. The patient presents on May 1, 2003 for hyperbaric oxygen therapy with residuals.**

#### **Patient Residuals**

- Left sided paresthasias with impaired motor function
- Decreased cognitive function
- Short term memory loss
- Bilateral peripheral blindness
- Left side partial denial

#### **HBOT Treatment Protocol**

- 40 HBOT
- BID / M-F
- 1.5 ATA
- 60 min. at Tx pressure
- Continued home exercise
- End HBOT May 29, 2003

#### **Patient Results**

- 100% return of peripheral vision
- Return of short term memory
- Capable of balancing check book
- Normal gait and balance
- Sensory/motor function significantly improved
- At 4 ½ months post stroke, patient was released to drive a car

#### **Additional Results**

- Surface rendering of the right hemisphere shows damage at the temporal region which was sustained after falling from a hay-loft 28 years prior the patient's stroke. No long-term deficits were noted after recovery from this injury. The post-HBOT image displays remarkable improvement of this 28-year old injury.