

Cerebral Vascular Accident — Left Side

A 62 year old male suffered a CVA in Feb 7, 2003. The patient presents on Feb 1, 2005 for hyperbaric oxygen therapy with residuals.

Patient Residuals

- Weakness right extremities
- Slurred speech
- Patient uses wheel chair and quad cane
- Decreased sensation in right extremity

HBOT Protocol

- 40 HBOT
- BID M/F
- 1.5 ATA
- 60 Min. at Tx pressure
- Continue physical therapy
- End HBOT Mar 2, 2005

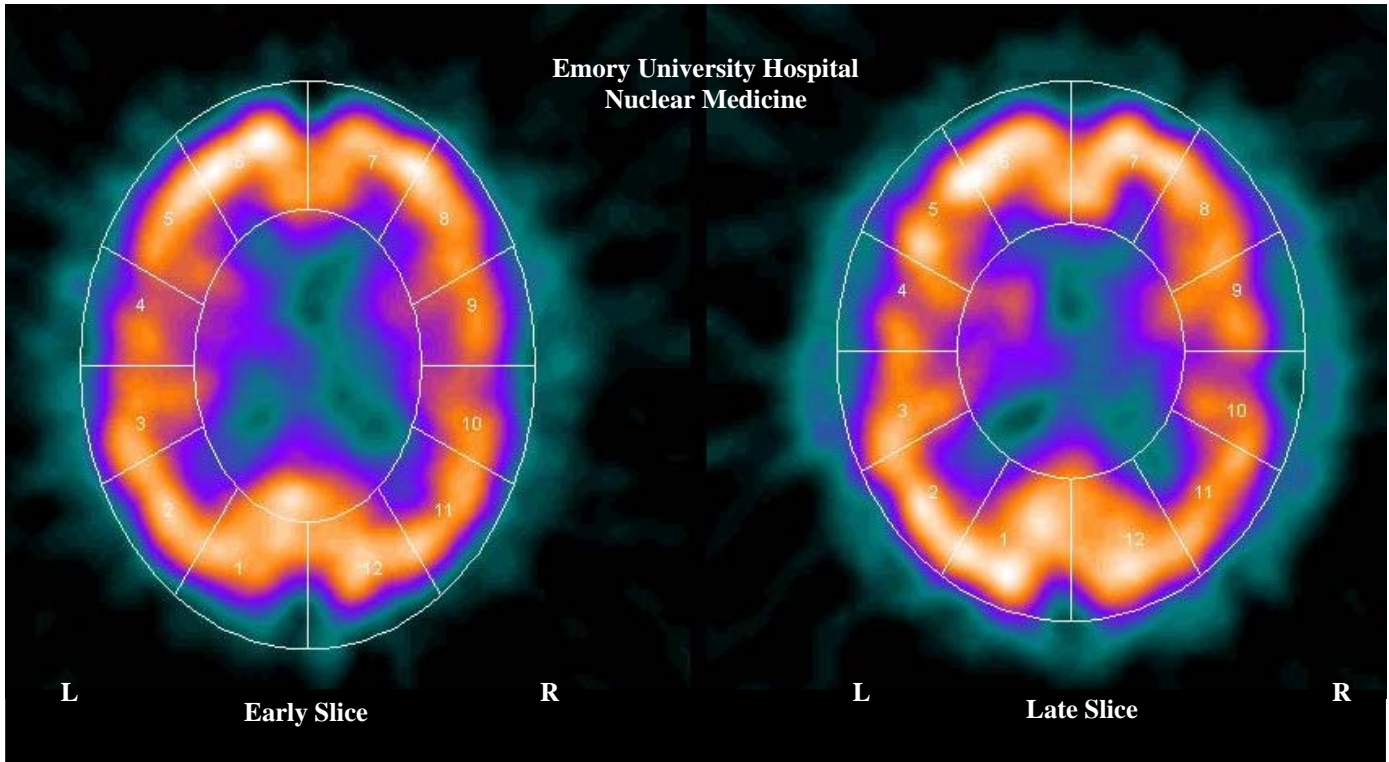
Patient Results

- Patient no longer using wheel chair
- Switched to single cane for mobility
- Resumed using heavier mechanic tools
- Patient can now remember past events
- Patient is walking better and has increased physical activity
- Returned to full time work

Additional Results

- “After HBOT, everyone is telling me how much better I am doing.” Pt states he is walking better, balance is improved and memory improving.





SPECT Scan Results		
Image A (<i>BBF = Brain Blood Flow</i>)		
BRAIN SEGMENT	BBF ↑	BBF ↓
1	30.5%	
2	6.06%	
3	0.14%	
4		.09%
5		0.62%
6		0.85%
7	0.87%	
8		1.47%
9		0.83%
10		3.16%
11	1.32%	
12	23.91%	

[Explanation of Brain Blood Flow](#)