

Cerebral Palsy

A 9 year old female with failure to thrive and resultant cerebral palsy presents on May 30, 2003 for hyperbaric oxygen therapy with residuals.

Patient Residuals

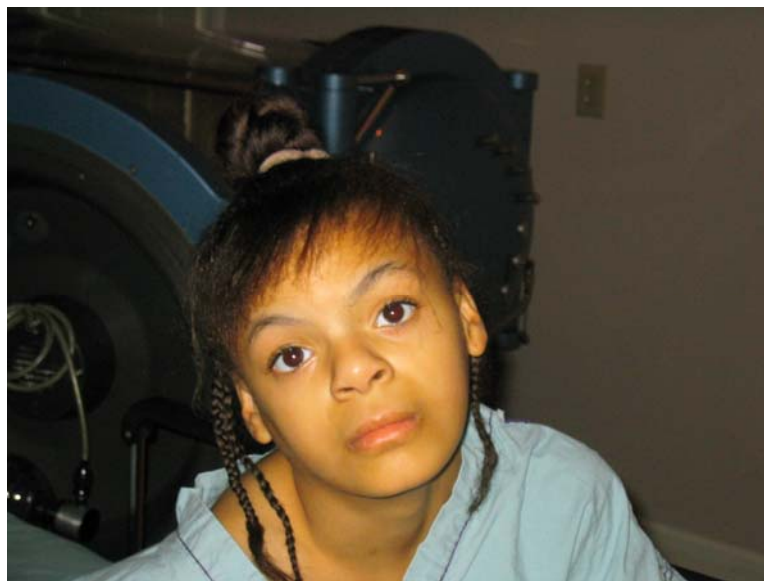- Failure to thrive
- Deteriorated speech patterns with productive babble
- Mild seizure activity
- Limited vocabulary
- Difficulty walking
- Hypotonia

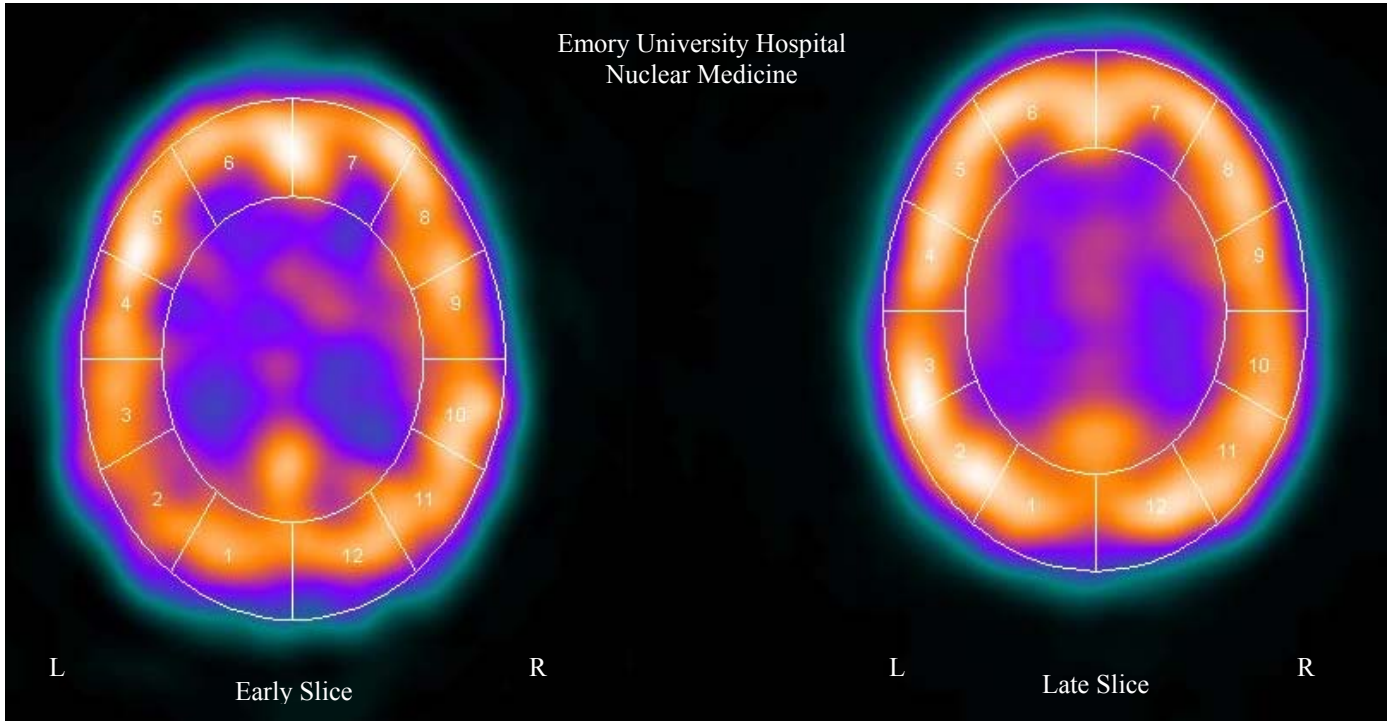
HBOT Protocol

- 40 HBOT
- BID M-F
- 1.5 ATA
- 60 Min at Tx pressure
- 35 Previous treatments at 1.6 ata
- End HBOT on Jan 20, 2004

Patient Results

- Mother reports 70% behavior improvement
- Seizure activity diminished
- Able to complete 20 pc puzzle
- Able to walk up stairs without assistance
- Walking with minimal assistance
- Integrated into more advanced education environment
- Expressing herself in 3-5 word sentences
- Able to kick a ball and learning to ride a bike





SPECT Scan Results		
<i>(BBF = Brain Blood Flow)</i>		
BRAIN SEGMENT	BBF ↑	BBF ↓
1	43.57%	
2	52.67%	
3	36.8%	
4	31.86%	
5	31.22%	
6	35.09%	
7	31.74%	
8	31.02%	
9	28.21%	
10	27.46%	
11	40.2%	
12	43.05%	

[Explanation of Brain Blood Flow](#)